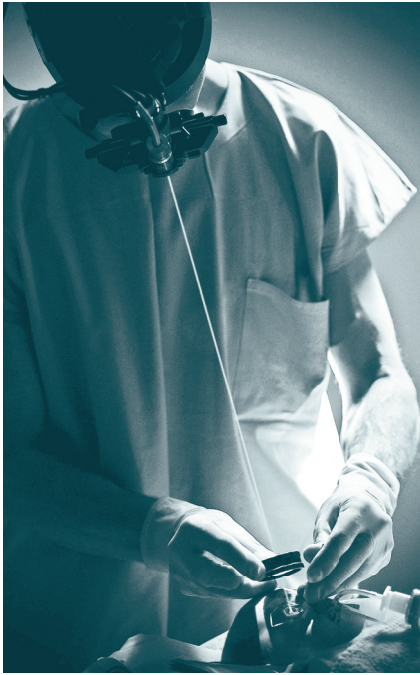



Laser assisted cataract surgery is a disruptive technology – but is it the way forward?

Laser Assisted Cataract Surgery: The Future?



Dr. Rick Wolfe

To its proponents, femtosecond laser-assisted cataract surgery (LACS) is said to be the future of cataract surgery, providing greater refractive accuracy, efficacy and safety. Opponents say they can get the same results with manual surgery. This apparently simple standoff should be easy to resolve, but there are many layers of complexity.

The idea that a laser might be used in cataract surgery to improve the outcomes is an irresistible one, and one that has a long history. Thirty-five years ago the neodymium-doped yttrium-aluminium-garnet (Nd:YAG) laser was reported as able to perform posterior capsulotomy in the pseudophakic patient.¹

Over 20 years ago Dr. Keith Zabell from Toowoomba, at the RACO (now RANZCO) Annual Scientific Meeting, presented results from the ISL picosecond neodymium-doped yttrium-lanthanum-fluorine (Nd:YLF) laser, which could perform capsulotomy and nuclear softening prior to phacoemulsification.^{2,3} While not appreciated at the time by many, the future of cataract surgery was being previewed.

Lasers have been introduced inside the eye on a probe as a substitute for ultrasound. The Dodick laser⁴ used an Nd:YAG laser firing at a titanium plate, causing shockwaves to emulsify the nucleus. I introduced the Erbium:YAG laser into Australia in 2000.⁵ It worked well breaking up the nucleus but, unfortunately, neither it nor the Dodick laser, while safe and effective, showed any real benefit over ultrasound phacoemulsification. The surgeons and manufacturers abandoned them.

It was the laser-assisted pre-treatment strategy – as we saw with the picosecond laser – that was pursued. Following the development and successful implementation of femtosecond lasers for LASIK flap creation, attention of manufacturers turned to further applications for this already successful technology.

THE FEMTOSECOND LASER (FSL)

Lasers are named in confusing ways. They can be named by the wavelength emitted, such as green or infrared, by the element causing the emission, such as argon or neodymium or in the case of the FSL, by the length of the pulse.

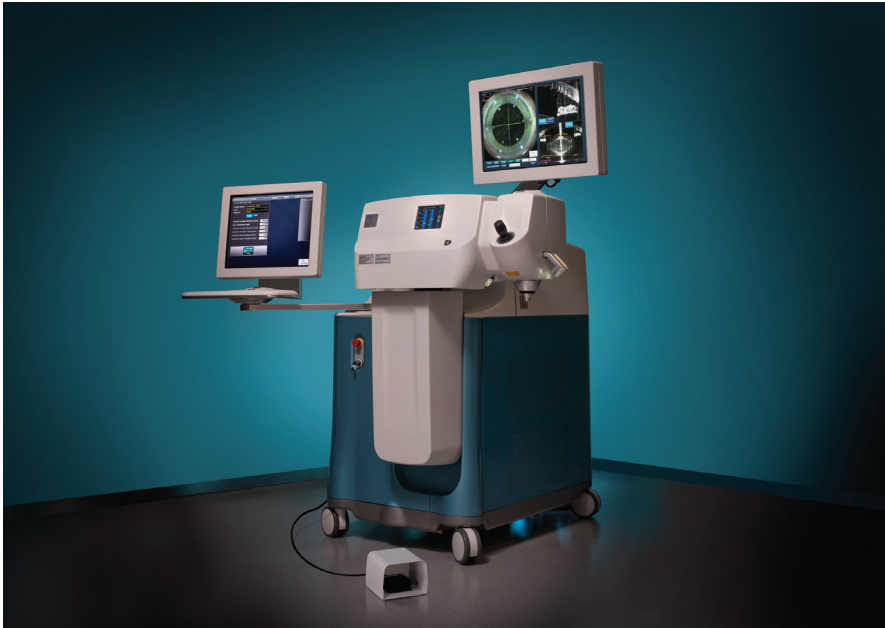Most FSLs are neodymium: glass 1053nm (near infrared). They typically focus a 3µm spot with an axial accuracy of just 5µm. Mode locking creates a pulse measured in femtoseconds (10⁻¹⁵ seconds). By comparison the Nd:YAG laser is a nanosecond laser working in the range of 10⁻⁹ second pulse length – a 10 million times longer pulse than the FSL! The shorter pulse is important as the threshold of energy required to cause photodisruption, or optical breakdown, is proportional to the pulse length. With a short pulse, photodisruption occurs at very low energy, minimising collateral damage to surrounding tissues.

“The idea that a laser might be used in cataract surgery to improve the outcomes is an irresistible one and one that has a long history”

FSLs for LACS all work with a repetition rate in a range from 50-160KHz. The laser ‘docks’ with the eye to maintain stability in x, y and z axes. The anterior segment is imaged, usually with OCT. The laser is guided by this image to ensure correct laser placement. Normally the laser creates the circular anterior capsulotomy, divides the lens nucleus in a variety of possible ways and creates the primary and secondary incisions. Arcuate keratotomy can be performed to treat pre-existing astigmatism after the other three functions have been completed.

The capsulotomy is normally completely divided and free, but the incisions require division of tiny tissue bridges with a spatula, and nuclear fragments usually require further division.

It is suggested that using these four applications LACS can be faster, safer and have better visual outcomes than manual surgery.⁶



Corneal incision Construction

The purported advantages of laser incision creation over manual incision is that they have better architecture creating better seal,⁷ lessening astigmatism induction and lessening the risk of descemet's membrane detachment and internal gape.

It can be difficult to make a manually created incision work as a self-sealing valve every time. An imperfect incision can leak and be the cause of potentially devastating endophthalmitis. A laser created incision might be more reliable and be protective.

Anterior Capsulotomy

It is no longer appropriate to leave a patient with astigmatism or with a significant deviation from spherical aim after surgery. Patients are no longer tolerating it, particularly the baby-boomers who represent a growing proportion of all cataract surgery.

Our methods of achieving the desired refractive aim are good but need improvement. A major barrier to eliminating post-operative astigmatism, which serves no useful purpose, has been eliminated with the recognition of the against the rule effect of the posterior cornea – a story for another day.⁸ Partial coherence interferometry for the measurement of axial length of the eye has improved our estimation of spherical IOL power but our lack of ability to predict the exact antero-posterior position the IOL will take up is our major problem.^{9,10} The FSL holds the promise of improving results.

Capsulorhexis is one of the most challenging parts of a manual cataract operation.¹¹ The size and circularity of the capsulorhexis in manual surgery influences outcomes. If the capsulorhexis is too large or asymmetric the IOL might be decentred, tilted or be too anteriorly placed. The anterior placement will result

in a myopic error. If the capsulorhexis is too small there can be a hyperopic outcome because of posterior malposition.¹² The exactness of the capsulotomy¹³ created by the FSL should make the position of the IOL more predictable with better refractive outcomes. This is particularly important with multifocal IOLs where problems of tilt and decentration have more impact on outcomes¹⁴ and create astigmatism and higher order aberrations (HOA).¹⁵

The capsulorhexis should always overlap the IOL edge to minimise posterior capsular opacity (PCO).^{9,12, 16-17} This should happen more often in LACS because of superior size and positioning accuracy.

In mature cataracts, attempted capsulotomy can suddenly tear to the periphery complicating the surgery enormously. It is termed the Argentinian flag sign after the white central split in the capsule and the surrounding capsule stained with trypan blue.¹⁸ These capsulotomies are often easy to complete safely with the FSL.

Without zonular counter traction loose cataracts can present real challenges to performing capsulorhexis. These are, doubtless, the most challenging cases in all of cataract surgery. For the FSL, capsulotomy is no problem.¹⁹ I find it hard to justify doing these cases any other way.

Nuclear division

In conventional surgery, the nucleus is chopped into four or more segments by a technique called phaco-chop. Introduced by Nagahara 20 years ago,²⁰ it was – according to several studies – responsible for reducing phaco times by up to half and nearly halving endothelial cell loss.²¹⁻²³ Phaco time is one of the indices we use to measure the amount of potentially damaging ultrasound energy released within the eye. The earlier technique of nuclear division, called 'divide and

conquer', involved sculpting and splitting of the nucleus. This is still in use by some surgeons.

The FSL chops the lens just like manual phaco-chop and holds the hope of reduced phaco times and lower endothelial cell loss just as with phaco-chop. For surgeons performing divide and conquer it offers a way to transition.

The nucleus can be radially divided or divided in a crisscross way. The optimal shape has not been determined but there is evidence that the ultrasound energy used is less than manual divide and conquer techniques.²⁴⁻²⁶ Studies, though, have not compared LACS phaco times with phaco-chop, which are probably comparable.²⁰⁻²² Less energy might result in lower endothelial cell loss.

Arcuate incisions

Arcuate corneal incisions for the correction of astigmatism can be made by the FSL. Astigmatic keratotomy (AK) made with blades has been associated with astigmatism reduction, but with significant inaccuracy.²⁷ It is envisaged that greater accuracy of cut depth provided by OCT-guided FSL will provide better results. Ventner²⁸ has shown improved results in treating post-cataract patients with mixed astigmatism using the FSL. The need for the function, however, is limited by the excellent accuracy of toric IOLs.

It is hoped that the benefits provided by these four functions will be reflected in outcomes of FSL surgery.

CURRENT STATE OF PLAY

The first FSL for LACS was installed in Sydney in April 2011. In Australia and New Zealand there are currently 23 FSLs: 17 LenSx lasers (Alcon Laboratories, Inc.), four Catalys lasers (AMO, Inc.) and two Lensar lasers (Lensar, Inc.). It is estimated that 10,000 of the 240,000 IOLs implanted last year (4.2 per cent) involved an FSL. Alcon claims it has trained 100 surgeons on its LenSx platform (9.9 per cent of 1,009 ophthalmologists in Australia and New Zealand).

THE EVIDENCE FOR LACS

A significant body of evidence in LACS has accumulated in the past few years. Some appears conflicting. Meta-analyses like Cochrane Reviews assess data for scientific worth and sources of bias and use statistical tools to assess reliability of the outcomes reported.

We are fortunate there exists such a review that has looked at 1,009 titles dating to September 2013.²⁹ Written for the US Veterans Affairs (VA) using Quality Enhancement Research Initiative's (QUERI) Evidence-based Synthesis Program (ESP), it was established to provide advice to policymakers. Asked by the study, was

whether LACS provides better efficacy and safety to conventional surgery.

As to efficacy, and after eliminating methodologically unsound papers and presentations, nine studies were identified,³⁰⁻³⁶ three of them randomised. Studies were conflicting as to corrected distance visual acuities (CDVA) and effective phaco time (EPT). The study concluded there was "...low evidence of benefit (of the FSL)..."

Nine papers were identified addressing safety comparisons.³¹⁻³⁹ The adverse event outcomes of these studies were grouped by the ocular structures that were affected. Reported were capsulotomy configuration, position and the resultant effects on IOL decentration and refractive outcomes, and post-operative corneal oedema, by measuring either corneal thickness or corneal endothelial cell loss and post-operative macular thickness and morphology, as measured by optical coherence tomography (OCT). The study reports: "The FSL and control groups were similar... Overall, we found moderate to low strength of evidence for comparative adverse events..."

Since September 2013, the cut-off for the review, there have been some interesting publications. Abell, in a very large cohort study of 4,000 cases, reveals very low complication rates of conventional and LACS.⁴⁰ There was an unusually high rate of anterior capsular tear but there was no negative visual impact on vision in these cases. The cause is not clear and not found in many other studies.

Reddy, in a randomised controlled study of 131 cataractous eyes, found lower EPT times for LACS, equivalent safety to conventional surgery, but with much improved capsulotomy centration and circularity.⁴¹

Chee in a cohort study of 1,105 eyes similarly found a high degree of safety for LACS and conventional cases performed at the Singapore National Eye Centre.⁴² Better UCVA was shown for both the 20/20 or better group and the 20/25 or

better group, which were both highly statistically significant.

USE OF EVIDENCE

The question: 'What level of evidence do we require to appropriately use a new drug, adopt a new technique or technology?' is an interesting one to ponder and not as straightforward as it first appears.

The question is not only important for surgeons but referring practitioners who are really partners in the process. The level of success reflects upon both of them as do negative outcomes.

"... enormous investment by suppliers and the vigorous completion has seen rapid introduction of software and hardware improvements in FSLs"

Clinical trials are essential, but long term results with very large numbers required to assess rare but serious complications, can only be determined after implementation of a technology. In the end, after considering the evidence, the test for the surgeon is whether he or she believes it is best for the patient.

The most important thing to take from the VA systematic review and meta-analyses²⁹ is the non-inferiority of LACS.

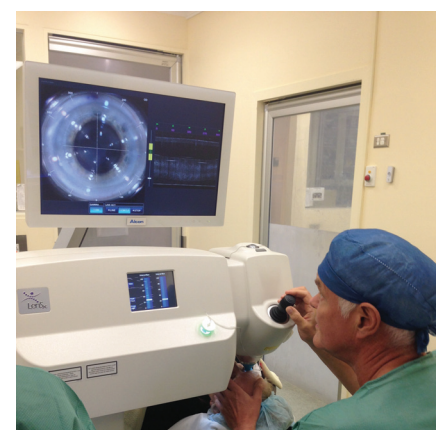
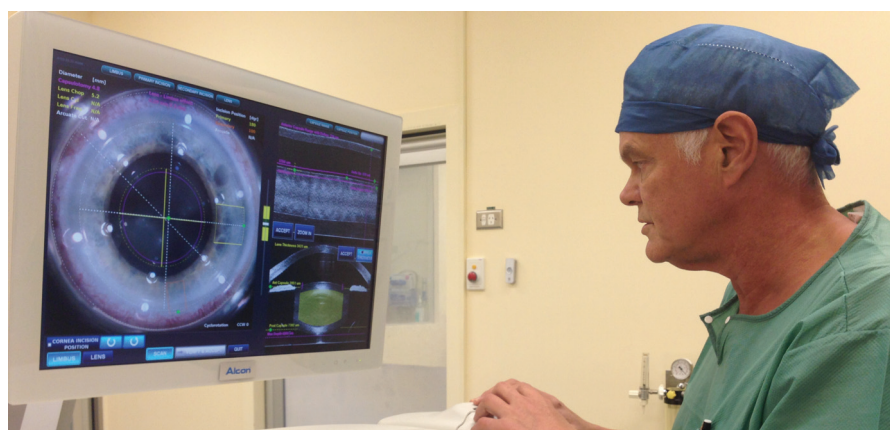
This evidence qualifies as NHMRC level one evidence. It is important to understand it is only answering specific questions and the answers are based on the available evidence.

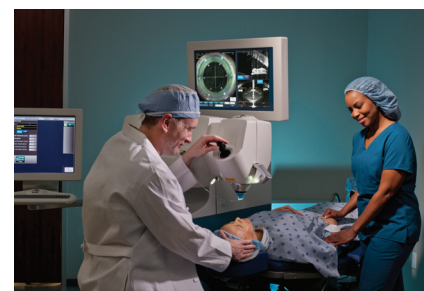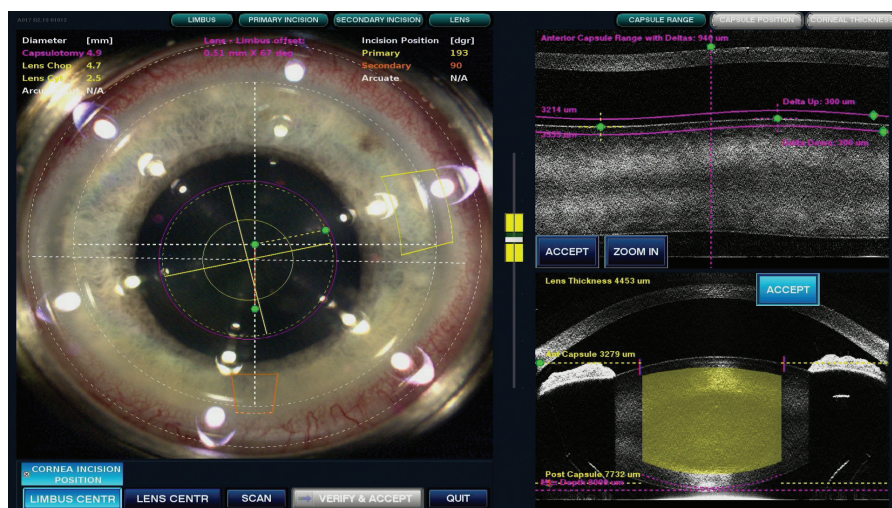
Experienced surgeons do the studies on selected good cases. Numbers are too small for the studies to have adequate power to determine if the rate of severe, blinding complications is reduced. One reviewer of the VA study makes this very point. Complex cases, where anecdotally I can say I wouldn't want to do the surgery any other way but LACS, are not represented in the studies looking at efficacy and safety. Many studies are not focused on the question of refractive accuracy, levels of visual quality or quality of life measures.

An interesting comparison to the introduction of LACS is the introduction of the FSL in LASIK. Surgeons were willing to spend \$500,000 on a machine, having to pay the supplier a 'per case' fee for permission to use their own machine, despite there being no good evidence in the literature to support its use. It sounds strange but there was a reason. Surgeons understand the variable outcomes they might have. What they have trouble with emotionally are severe, sight-threatening complications of their surgery. A manual microkeratome is very safe but very rarely buttonholes, irregular, truncated and lost flaps can happen. These are devastating to all concerned, and can't really happen with the FSL. This difference between microkeratome and FSL is not reflected in the compared outcomes literature. This consideration, I believe, is behind the thinking of many early adopters of LACS where too, the literature is of no help, but a desire to reduce serious complications is paramount in surgeons' minds.

A different dynamic was seen with the introduction of phacoemulsification where the superior results were immediately obvious. Safety and efficacy figures eventually emerged. Opposition to the new, disruptive technology was fierce and took a decade to die out. Again the test for the surgeon is: Based on what he or she knows, what is the best for the patient?

Simple examination of level one evidence might help support third party payers in refusing access (or payment for) technology, but it is inadequate for





surgeons, whose primary concern is their individual patient.

SOME CONCERNS

Abell's group suffered a high anterior capsular tear rate.⁴⁰ They pointed to irregularities of laser-created anterior capsulotomies as potentially weak points.⁴³ Other groups generally had not had these high anterior capsular tear rates. Indeed Auffarth showed in porcine eyes stronger capsulotomies in laser eyes than with manual capsulorhexis.⁴⁴ Sandor, in a similar study showed slightly weaker capsulotomy in laser eyes, but the weakest of the capsulotomies were found in the manually created group.⁴⁵ If indeed LACS capsulotomies were weaker it would have represented a major drawback of LACS, as the intact anterior capsulorhexis is one of the foundations of modern cataract surgery.

Early in the evolution of LACS, Roberts very responsibly reported two cases of posterior capsular rupture at the time of hydrodissection.⁴⁶ This step of the procedure involving injection of fluid under the capsule, frees the lens from the capsular bag for safe removal. These two cases caused understandable concern that there was fundamental fault in LACS. Some authors even reported eliminating this step.⁴¹ It would have been a very serious problem for LACS had cases continued, as hydrodissection is another fundamentally important part of modern cataract surgery. Roberts suggested better technique for hydrodissection and it seems not to have been a problem since.⁴⁶

LACS presents special difficulties in two situations. Small pupils limit capsulotomy and nuclear splitting by their size. Normally manual surgery is selected in these cases, but Conrad-Hengerer has reported techniques of pharmacologically and surgically dilating the pupil before the laser is applied.⁴⁷

Corneal irregularities and scars such as those after keratoplasty can present

a problem for LACS as they can block and scatter the infrared femtosecond pulses. These cases are often better done manually. An inadequate laser capsulotomy is arguably worse than not having performed one at all and having to do it manually.

“For difficult cases such as endothelial dystrophy, mature cataracts and lenses with poor zonular support there are clear advantages of LACS”

THE FUTURE

The clear and proven non-inferiority of LACS, and significant evidence of its superiority is just the beginning. The enormous investment by suppliers and the vigorous completion has seen rapid introduction of software and hardware improvements in FSLs, which have improved the surgery.

The reduction in ultrasound power is a goal. This might reduce endothelial cell loss and oedema further and provide quicker recovery and safer surgery. Already Abell^{24,48} has been able to reduce EPT by 70 per cent. The aim of zero phaco might be achieved with improved FSL nuclear division strategies and larger bore aspiration so fragments left after laser fragmentation can be aspirated without engaging ultrasound energy.

Dick has successfully performed posterior capsulotomy in paediatric eyes.⁴⁹ The capsulotomy is analogous to the notoriously technically difficult posterior capsulorhexis of manual surgery. This might well translate into better paediatric cataract surgery in the future.

A problem in lens surgery, particularly with multifocal IOLs, is centration.¹⁵ IOLs sit in the centre of the bag giving temporal decentration with reference to the nasally displaced pupil. Dick has used a new IOL, the 90F (Morcher GmbH, Stuttgart, Germany) in LACS.⁵⁰ This IOL sits in the bag but is fixated within the capsulotomy. The advantages might be certain centration where desired, say the pupil centre, and more predictable anterior-posterior position, possibly translating into better IOL power prediction. Only the FSL can produce a capsulotomy of the exact size and circularity required for implantation and the centration desired for maximum optical advantage. This might well be the future of IOL implantation.

THE COST

In Australia, patients make a co-payment for use of the FSL. It ranges from AU\$600–\$1,000. Some surgeons offer LACS as an option and others only offer LACS, where indicated, including the additional cost in their fee.

From a public health perspective it is calculated in the USA that the cost of cataract surgery performed manually is US\$1,600 per quality-adjusted life-year (QALY).⁵¹ A QALY of up to \$50,000 is considered by the World Health Organization as reasonable for any intervention in Australia, so it is clear how cost-effective cataract surgery is.


Abell and Vote calculated LACS in Australia to cost \$96,862 per QALY and concluded that the per case fee would have to drop to \$300, assuming perfect outcomes and zero complications for LACS, to achieve a reasonable cost per QALY to be acceptable in a public health sense.⁵²

It is estimated that the overall cost per case in the USA is \$1,000 for 250 cases per year, reducing below \$500 per year for an FSL performing 2,500 cases per year.⁵³ The cost structure is similar in Australia, so the aim of \$300 per case might be difficult to achieve.

CONCLUSIONS

LACS is growing despite significant opposition within the profession. It is a disruptive technology and opposition is understandable. It has occurred with every major improvement. We need to be critical and scientific in our judgment and we need to understand that if LACS is simply unnecessary technology foisted upon us by industry, then it cannot survive.

There is no doubt we need better refractive outcomes. No one could argue that a safer procedure is desirable. For difficult cases such as endothelial dystrophy, mature cataracts and lenses with poor zonular support, there are clear advantages of LACS. If a procedure is good for the difficult cases it follows that it is good, too, for regular cases.

The important thing to decide is not if results of surgery, as published in the literature, are so much better than manual surgery, but whether the FSL is the platform with which we move forward in lens surgery. Everything I have seen makes me think this might be so. 

Dr. Rick Wolfe MB BS FRACS FRANZCO is one of Australia's most experienced cataract and refractive surgeons. He has performed more than 10,000 cataract procedures and over 17,000 LASIK procedures during the past 25 years while practising as an ophthalmic surgeon. Dr. Wolfe has given more than 20 years service to the Royal Australian Navy Reserve, where he holds the rank of Lieutenant Commander. In 2004 he performed live laser surgery in front of 2,000 of his colleagues at The American Society of Cataract and Refractive Surgeons (ASCRS) in San Diego. Dr. Wolfe regularly speaks at conferences, including ASCRS, AUSCRS (Australasian Society of Cataract and Refractive Surgeons) and Alcon in Hong Kong. His private practice at Peninsula Eye Centre, Mornington, Victoria and his laser eye surgery practice at VISTA Eyes Elsternwick Victoria is limited to cataract and refractive surgery.

References

1. Aron-Rosa D, Aron JJ, Griesemann M, Thyzel R. Use of the neodymium:YAG laser to open the posterior capsule after lens implant surgery: a preliminary report. *J Am Intraocul Implant Soc* 1980; 6: 352–354.
2. Zabell K Presentation RACO Annual Scientific Meeting November 1993
3. Greeling G Initial clinical experience with the picosecond Nd:YLF laser for intraocular therapeutic applications *Br J Ophthalmol*. 1998 May; 82(5): 504–509.
4. Dodick JM. Laser phacolysis of the human cataractous lens. *Dev Ophthalmol* 1991; 22: 58–64.
5. Vergés C, Llevat E. Laser cataract surgery: technique and clinical results. *J Cataract Refract Surg*. 2003 Jul;29(7):1339-45.
6. Naranjo-Tackman R. How a femtosecond laser increases safety and precision in cataract surgery? *Curr Opin Ophthalmol* 2011; 23: 53–57
7. Masket S, Sarayba M, Ignacio T, Fram N. Femtosecond laser-assisted cataract incisions: architectural stability and reproducibility. *J Cataract Refract Surg* 2010; 36:1048–1049
8. Koch D, Jenkins RB, Mitchell P, Weikert MP, Yeu E, Li Wang. Correcting astigmatism with toric intraocular lenses: Effect of posterior corneal astigmatism. *J Cataract Refract Surg* 2013; 39:1803–1809
9. Cekic O, Batman C. The relationship between capsulorhexis size and anterior chamber depth relation. *Ophthalmic Surg Lasers* 1999; 30(3): 185–190.

10. Norrby S. Sources of error in intraocular lens power calculation. *J Cataract Refract Surg* 2008; 34: 368–376.
11. Dooley IJ, O'Brien PD. Subjective difficulty of each stage of phacoemulsification cataract surgery performed by basic surgical trainees. *J Cataract Refract Surg* 2006; 32: 604–608.
12. Sanders DR, Higginbotham RW, Opatowsky IE, Confino J. Hyperopic shift in refraction associated with implantation of the single-piece Collamer intraocular lens. *J Cataract Refract Surg* 2006; 32: 2110–2112.
13. Nagy Z, Takacs A, Filkorn T, Sarayba M. Initial clinical evaluation of an intraocular femtosecond laser in cataract surgery. *J Refract Surg* 2009; 25: 1053–1060.
14. Lakshminarayanan V, Enoch JM, Raasch T, Crawford B, Nygaard RW. Refractive changes induced by intraocular lens tilt and longitudinal displacement. *Arch Ophthalmol* 1986; 104(1): 90–92.
15. Baumeister M, Bühren J, Kohner T. Tilt and decentration of spherical and aspheric intraocular lenses: effect on high-order aberrations. *J Cataract Refract Surg* 2009; 35: 1006–101
16. Walkow T, Anders N, Pham DT, Wollensak J. Causes of severe decentration and subluxation of intraocular lenses. *Graefes Arch Clin Exp Ophthalmol* 1998; 236: 9–
17. Ravalico G, Tognetto D, Palomba M, Busatto P, Baccara F. Capsulorhexis size and posterior capsule opacification. *J Cataract Refract Surg* 1996; 22(1): 98–103.
18. Chakrabarti A, Singh S, Krishnadas R. Phacoemulsification in eyes with white cataract. *J Cataract Refract Surg* 2000; 26:1041–1047
19. Schultz T, Ezeanosike E, Dick HB. Femtosecond Laser-Assisted Cataract Surgery in Pediatric Marfan Syndrome. *J Refract Surg*. 2013;29(9):650-652.
20. Nagahara K Phaco Chop Film presented at International Congress on Cataract, IOL and Refractive Surgery ASCRS, May 1993; Seattle WA USA.
21. Park J, Comparison of phaco-chop, divide-and-conquer, and stop-and-chop phaco techniques in microincision coaxial cataract surgery. *J Cataract Refract Surg* 2013; 39:1463–1469
22. Wong T, Hingorani M, Lee V. Phacoemulsification time and power requirements in phaco chop and divide and conquer nucleofractis techniques. *J Cataract Refract Surg* 2000; 26:1374–1378
23. DeBry P Comparison of energy required for phaco chop and divide and conquer phacoemulsification. *J Cataract Refract Surg* 1998; 24:689-692
24. Abell RG, Kerr NM, Vote BJ. Toward zero effective phacoemulsification time using femtosecond laser pretreatment. *Ophthalmology* 2013; 120:942 – 948.
25. Conrad-Hengerer I, Hengerer FH, Schultz T, Dick HB. Effect of femtosecond laser fragmentation on effective phacoemulsification time in cataract surgery. *J Cataract Refract Surg* 2012; 28:879–883.
26. Conrad-Hengerer I, Hengerer FH, Shultz T, Dick HB. Effect of femtosecond laser fragmentation of the nucleus with different softening grid sizes on effective phaco time in cataract surgery. *J Cataract Refract Surg* 2012; 38:1888 – 1894.
27. Agapitos PJ, Lindstrom RL, Williams PA, Sanders DR. Analysis of astigmatic keratotomy. *J Cataract Refract Surg*. 1989 Jan;15(1):13-8
28. Venter J, Blumenfeld R, Schallhorn S, Pelouskova M. Non-penetrating femtosecond laser intrastromal astigmatic keratotomy in patients with mixed astigmatism after previous refractive surgery. *J Refract Surg*. 2013 Mar;29(3):180-6.
29. Quiñones A, Gleitsmann K, Freeman M, Fu R, O'Neil M, Motu'apuaka M, Kansagara D. Benefits. [Internet]. Washington (DC): Department of Veterans Affairs; 2013 Dec.PMID: 24575450 Available at: www.ncbi.nlm.nih.gov/pubmedhealth/PMH0063227/pdf/TOC.pdf Accessed Jan 26 2014
30. Abell RG, Kerr NM, Vote BJ. Catalys femtosecond laser-assisted cataract surgery compared to conventional cataract surgery. *Clin Experiment Ophthalmol*. Oct 19 2012.
31. Filkorn T, Kovacs I, Takacs A, Horvath E, Knorz MC, Nagy ZZ. Comparison of IOL power calculation and refractive outcome after laser refractive cataract surgery with a femtosecond laser versus conventional phacoemulsification. *Journal of Refractive Surgery*. Aug 2012;28(8):540-544.
32. Kranitz K, Mihaltz K, Sandor GL, Takacs A, Knorz MC, Nagy ZZ. Intraocular lens tilt and decentration measured by Scheimpflug camera following manual or femtosecond laser-created continuous circular capsulotomy. *J Refract Surg*. Apr 2012;28(4):259-263.
33. Abell RG, Kerr NM, Vote BJ. Toward Zero Effective Phacoemulsification Time Using Femtosecond Laser Pretreatment. *Ophthalmology*. May 2013;120(5):942-948.
34. Mihaltz K, Knorz MC, Alio JL, et al. Internal aberrations and optical quality after femtosecond laser anterior capsulotomy in cataract surgery. *Journal of Refractive Surgery*. Oct 2011;27(10):711-716.
35. Takacs AI, Kovacs I, Mihaltz K, Filkorn T, Knorz MC, Nagy ZZ. Central corneal volume and endothelial cell count following femtosecond laser-assisted refractive cataract surgery compared to conventional phacoemulsification. *Journal of Refractive Surgery*. Jun 2012;28(6):387-391.
36. Ecsedy M, Mihaltz K, Kovacs I, Takacs A, Filkorn T, Nagy ZZ. Effect of femtosecond laser cataract surgery on the macula. *Journal of Refractive Surgery*. Oct 2011;27(10):717-722.
37. Nagy ZZ, Ecsedy M, Kovacs I, et al. Macular morphology assessed by optical coherence tomography image segmentation after femtosecond laser-assisted and standard cataract surgery. *Journal of Cataract & Refractive Surgery*. Jun 2012;38(6):941-946.
38. Conrad-Hengerer I, Hengerer FH, Schultz T, Dick HB. Effect of femtosecond laser fragmentation of the nucleus with different softening grid sizes on effective phaco time in cataract surgery. *Journal of Cataract & Refractive Surgery*. Nov 2012;38(11):1888-1894.
39. Kranitz K, Takacs A, Mihaltz K, Kovacs I, Knorz MC, Nagy ZZ. Femtosecond laser capsulotomy and manual continuous curvilinear capsulorhexis parameters and their effects on intraocular lens centration. *Journal of Refractive Surgery*. Aug 2011;27(8):558-563.
40. Abell RG, Darian-Smith E, Kan JB, Allen PL, Ewe SY, Vote BJ. Femtosecond laser-assisted cataract surgery versus standard phacoemulsification cataract surgery: outcomes and safety in more than 4000 cases at a single center. *J Cataract Refract Surg*. 2015 Jan;41(1):47-52.
41. Reddy KP, Kandulla J, Auffarth GU. Effectiveness and safety of femtosecond laser-assisted lens fragmentation and anterior capsulotomy versus the manual technique in cataract surgery. *J Cataract Refract Surg*. 2013 Sep;39(9):1297-306
42. Chee SP, Yang Y, Ti SE. Clinical Outcomes in the first 2 years of Femtosecond Laser-assisted Cataract Surgery. *Am J Ophthalmol*. 2015 Jan 26. [Epub ahead of print]
43. Abell RG, Davies PEJ, Phelan D, Goemann K, McPherson Z, Vote B. Anterior Capsulotomy Integrity after Femtosecond Laser-Assisted Cataract Surgery. *Ophthalmology* 2014;121:17-24
44. Auffarth GU, Reddy KP, Ritter R, Holzer MP, Rabsilber TM. Comparison of the maximum applicable stretch force after femtosecond laser-assisted and manual anterior capsulotomy. *J Cataract Refract Surg* 2013; 39:105–109
45. Sándor GL, Kiss Z, Zoltán I, Bocskai ZI, Kolev K, Takács AI, Juhász E, Kránitz K, Tóth G, Gyenes A, Bojtár I, Juhász T, Nagy ZZ. Comparison of the Mechanical Properties of the Anterior Lens Capsule Following Manual Capsulorhexis and Femtosecond Laser Capsulotomy. *J Refract Surg*. 2014;30(10):660-664
46. Roberts TV, Sutton G, Lawless MA, Jindal-Bali S, Hodge C. Capsular block syndrome associated with femtosecond laser-assisted cataract surgery. *J Cataract Refract Surg* 2011; 37:2068–2070
47. Conrad-Hengerer I, Hengerer F H, Schultz T, Dick H B. J Cataract Femtosecond laser-assisted cataract surgery in eyes with a small pupil. *J Refract Surg* 2013; 39:1314–1320
48. Abell RG, Kerr NM, Vote BJ. Femtosecond laser-assisted cataract surgery compared with conventional cataract surgery. *Clin Experiment Ophthalmol*. 2013 Jul;41(5):455-62
49. Dick HB, Schultz T. Femtosecond laser-assisted cataract surgery in infants. *J Cataract Refract Surg* 2013; 39:665–668
50. Dick HB, Schultz T. Intraocular Lens Fixated in the Anterior Capsulotomy Created in the Line of Sight by a Femtosecond Laser Refract Surg. 2014;30(3):198-201
51. Brown GC. Cataract Surgery Cost Utility Revisited in 2012. *A New Economic Paradigm Ophthalmology* 2013;120:
52. Abell RG, Vote BJ. Cost-Effectiveness of Femtosecond Laser-Assisted Cataract Surgery versus Phacoemulsification. *Cataract Surgery Ophthalmology* 2013;1-7 2367-2376
53. Are Lasers Good Business? *Eyenet* July 2013: 44-50 American Academy of Ophthalmology